

**THE BIOMARKERS FOR EARLY PREDICTION AND DIAGNOSE FOR  
NECROTIZING ENTEROCOLITIS IN NEWBORNS**

**HARUTYUNYAN A.S.<sup>1,4\*</sup>, MURADYAN A.A.<sup>2</sup>, BADALYAN A.R.<sup>3</sup>, BABLOYAN A.S.<sup>4</sup>,  
KALENTERYAN H.Z.<sup>5</sup>, SARGSYAN K.V.<sup>6</sup>**

<sup>1</sup> Department of Pediatric Surgery,

<sup>2</sup> Department of Urology and Andrology,

<sup>3</sup> Department of Epidemiology, Faculty of Public Health,

<sup>4</sup> Department of Pediatric Surgery, "Muratsan" clinical complex,

<sup>5</sup> The Clinic of Neonatology Intensive Care Unit, "Muratsan" clinical complex,

**of Yerevan State Medical University after M. Heratsi, Yerevan, Armenia**

<sup>6</sup> Biobank Graz, Medical University Graz, Austria

Received 16.01.2020; accepted for printing 14.07.2020

**ABSTRACT**

*Necrotizing enterocolitis is a devastating disease that affects mostly the intestine of premature infants. The wall of the intestine is damaged by hypoxia, and bacteria are invaded, which cause local inflammation and infection that can ultimately destroy with necrosis the wall of the intestine. Such bowel wall destruction can lead to perforation of the intestine and spillage of stool into the infant's abdomen, which can result in an overwhelming infection and death.*

*The clinical presentation of necrotizing enterocolitis includes variable signs, which are often non-specific for gastrointestinal dysfunction. The clinical diagnosis of necrotizing enterocolitis is currently made based on a combination of clinical, laboratory, and instrumental (ultrasound and radiologic) findings.*

*The preventive multi-modal 3-component necrotizing enterocolitis prophylaxis scheme was implemented for necrotizing enterocolitis treatment in December of 2016 in Neonates Intensive Care Unit of "Muratsan" clinical complex of Yerevan State Medical University resulted in significantly reduced necrotizing enterocolitis-associated morbidity and mortality.*

*Necrotizing enterocolitis is severe disease of gastrointestinal tract, yet its early symptoms are nonspecific, easily interchangeable with sepsis. Therefore, reliable biomarkers for early diagnostics are needed in clinical practice.*

*One of the promising trends in early diagnosis of necrotizing enterocolitis is use of biomarkers. The biomarkers used in prognosis and diagnosis of necrotizing enterocolitis are relative nonspecific as other noninvasive and less invasive methods. Amongst variety of biomarkers molecules, based on literature, one of the most promising for necrotizing enterocolitis seems to be intestinal fatty acid-binding protein.*

*In modern days, biomarkers widely used for diagnose and prediction in many diseases. Necrotizing enterocolitis is one of the most severe acquired diseases affecting preterm neonates. Early diagnosis remains elusive which continues to prompt human subject studies in the search for necrotizing enterocolitis-associated biomarkers that may provide for early diagnosis or the recognition of high-risk subcohorts with sufficient precision to facilitate preventive measures.*

**Keywords:** necrotizing enterocolitis, newborns, biomarkers, intestinal fatty acid-binding protein.

**INTRODUCTION**

Necrotizing enterocolitis (NEC) is a devastating disease that affects mostly the intestine of pre-

**Address for Correspondence:**

Dr. Arman S. Harutyunyan  
"Muratsan" clinical complex, Yerevan State Medical  
University, 114 Muratsan Street, Yerevan 0075,  
Armenia  
Tel.: (+374 10) 45-33-02; Fax: (+374 10) 56-52-47  
E-mail: armansgn@yahoo.com

mature infants. The wall of the intestine is damaged by hypoxia, and bacteria are invaded, which cause local inflammation and infection that can ultimately destroy with necrosis the wall of the intestine. Such bowel wall destruction can lead to perforation of the intestine and spillage of stool into the infant's abdomen, which can result in an overwhelming infection and death [Josef N, 2005].

**Relevance of the problem:** Despite of history

of about 200 years necrotizing enterocolitis is still remains a major concern for neonatologists, pediatric surgeons and gastroenterologists due to its high morbidity and mortality. These infants often have poor developmental outcome, and contribute to significant economic burden resulting in marked stress in these families. By developing and adhering to strict feeding protocols, encouraging human milk feeding preferably from the infant's mother, use of probiotics, judicious antibiotic use, instituting blood transfusion protocols, the occurrence of NEC may possibly be reduced. However, because of its multifactorial etiology, it cannot be completely eradicated in the NICUs, particularly in the extremely premature infants. Ongoing surveillance of NEC and quality improvement projects may be beneficial [Huda S. et al., 2014].

All premature infants are at risk of NEC, but incidence and mortality rates differ significantly throughout the world. In the United States alone, the incidence rate for NEC varies between 3 and 10% annually across most series with a mortality of up to 33% [Fitzgibbons S et al., 2009] and at an estimated cost to the US healthcare system of more than 1 billion dollars [McElroy S, 2014]. In the United Kingdom (UK), 163 English neonatal departments prospectively collected information on 118,073 newborns over two years and reported on 531 infants (0.4%) who developed severe NEC with a mortality of 48% [Battersby C et al., 2017]. In China, the incidence rate of NEC is 4.5% and 2.5% in very low-birth weight (very low birth weight, birth weight less than 1500g) and low-birth weight (low birth weight, birth weight less than 2500g) neonates, respectively, and the mortality rate of NEC at stages II and III was 41.7% [Qian T et al., 2017]. In infants born at a gestational Age of less than 28 weeks, the lowest reported incidence of NEC was in Japan (2%) and the highest in Australia, Canada, and Italy (7-9%) [Battersby C et al., 2018].

The pathogenesis refers to the interaction of three aspects: intestinal ischemia, inflammation and necrosis [Schmolzer G et al., 2006]. There is an assumption that NEC occurs by the interaction of three events: Initially a mucosal injury occurs due to intestinal ischemia, followed by inflammation of the disturbed mucosal integrity with subsequent necrosis of the affected area. The further steps are colonization by pathogenic bacteria and excess protein substrate in the intestinal lumen. Furthermore, the immunologic immaturity of the neonatal gut has been implicated in the development of NEC [Berrington J, 2017].

The usual onset of this disease is between 7th and 14th day of life, although later onset of NEC was documented in literature. The clinical presentation of NEC includes variable signs, which are often non-specific for gastrointestinal dysfunction [Claud C, 2009]. According to Bell M. and co-authors, NEC is classified into 3 stages. Especially stages 3A and 3B are advanced stages of disease, and are associated with a high mortality, since they lead to intestinal perforation with peritonitis, to septic shock and the need for surgical interventions [Bell M et al., 1978].

Potential risk factors for NEC include very low birth weight [Stoll B et al., 2015], prematurity [Sankaran K et al., 2004], formula feeding [Good M et al., 2014; Berkhout D et al., 2018], hypoxic/ischemic insults [Yu Y et al., 2015], infection [Eaton S et al., 2017] and microbial dysbiosis [Elgin T et al., 2016; Warner B et al., 2016; Neu J et al., 2017].

The clinical diagnosis of NEC is currently made based on a combination of clinical, laboratory, and instrumental (ultrasound and radiologic) findings. Typical clinical signs include abdominal distension, bile- or blood-stained emesis or gastric aspirate, abdominal wall erythema and bloody stools. Diagnosis is based on radiographic evidence as bowel distension, ileus, pneumatosis intestinalis and/or bowel perforation [Schmolzer G et al., 2006]. Abdominal X-ray and ultrasound have been shown to be useful in helping to monitor the progression of the disease and detecting the presence of NEC. The radiological imaging studies to identify NEC are dilated loops of bowel, pneumatosis intestinalis, portal venous gas and intestinal perforation [Janssen L et al., 2018].

Neonates who develop intestinal perforation (Bell stage IIIB), have suspected bowel necrosis, or fail to respond to medical treatment require surgical treatment – “surgical NEC”. Specific surgical treatments have not changed since the 1970's and generally include either bedside peritoneal drain placement or standard laparotomy. If laparotomy is performed, the most common management is resection of grossly diseased intestine and creation of ostomies. Among infants with very low birth weight, 27-52% requires

surgical intervention, and the survival of very low-birth weight neonates with perforated NEC may be more dependent on clinical status than on treatment modality [Robinson J *et al.*, 2017].

The 5-years systematic review article presented contemporary outcome numbers for infants with NEC in a third level University Neonatal Intensive Care Unit (NICU) at the Muratsan Clinical Complex of Yerevan State Medical University in Yerevan, Armenia, showed that out of 3028 admitted newborn infants, 213 (7%) presented with a diagnosis of NEC. From these 213 patients, 11 (5%) were term-born infants, and 77 (36%) died, thus showing a high NEC-associated mortality rate in Armenia. It is well known that preterm infants with NEC not only have a high mortality but also a high morbidity, with significantly longer hospitalization times and significantly higher treatment costs compared to infants without NEC [Harutyunyan A, 2017].

The retrospective study was performed to assess and compare histological (autopsy) and clinical data among newborns with necrotizing enterocolitis over 2016-2017 periods – born in 21 deliveries hospitals, newborns admitted to NICU of “Muratsan” clinical complex of Yerevan State Medical University aft. M. Heratsi and autopsy data of medical centre “Arabkir”. The aim of the study was to compare the histological (autopsy) and clinical data in neonates with necrotizing enterocolitis. The results showed: In 73 (86.9% out of 84 cases) newborns the NEC was diagnosed during autopsy and histological examination. The histological diagnose NEC matched with referral diagnose in 27 cases – 37% (out of 73 cases). In 46 (63% out of 73 newborns) cases NEC was present during autopsy and histological examination, but didn't manifested clinically or was not diagnosed before death. In other findings 42 cases out of 142 lethal newborns during the autopsy the histological signs of different stages of NEC were detected, but were not included in clinical diagnose. The results of the study denote that a high proportion of the incompatibilities of NEC diagnosis can be attributed to diagnostic limitations and are potentially avoidable with use of modern diagnostic techniques [Harutyunyan A *et al.*, 2019a].

Several studies have identified interventions that resulted in reductions of the incidence of NEC, such as breast milk feeding, use of probiotics, progression of enteral feeds and enteral antibiotic prophylaxis [Schmolzer G *et al.*, 2006].

Due to the high incidence of NEC and high NEC-associated mortality in Armenia, some doctors from Armenia spent an observer ship period at the Medical

University of Graz, Austria, at the Department of Pediatric Surgery and the Division of Neonatology. In these two units in Austria, they saw the use of a NEC prevention protocol, which had been used over the last 20 years, and which resulted in a very low incidence of NEC of 1% in preterm neonates less than 1500g [Schmolzer G *et al.*, 2006]. The Graz protocol is a multi-modal three-component regimen for NEC prevention and consists of enteral application of a probiotic in combination with enteral application of an antibiotic and an antifungal substance. Based on the data of the Medical University of Graz, the multi-modal three-component regimen for NEC prevention was introduced at the NICU of Muratsan Clinical Complex at Yerevan State Medical University, Armenia [Harutyunyan A *et al.*, 2018]. The Muratsan Clinical Complex is the main level III referral hospital for neonates in Armenia. As no neonates are born in the clinical complex, the multi-modal three-component enteral medication regimen was initially introduced in neonates who had been transferred to the hospital, and in which the diagnosis of NEC (of any stage according to Bell's criteria) was already established. Thus, the regimen was not used as preventive medication, as published by Schmolzer G. and co-authors, but as a therapeutic approach for the first time [Harutyunyan A *et al.*, 2019c].

The Graz protocol of multi-modal three-component regimen for NEC prevention consists originally of enteral application of a probiotic, *Lactobacillus rhamnosus*, in combination with enteral application of an antibiotic, gentamicin and an antifungal substance, nystatin [Schmolzer G *et al.*, 2006]. For the implementation at the Muratsan Clinical Complex in Armenia, the Austrian protocol was revised as the same probiotic was not available in Armenia. It was therefore replaced with the synbiotic LactoG, which was locally available. This synbiotic consists of a prebiotic, fructooligosaccharide, in a 37.5 mg/capsule and probiotics containing the following strains: *Bifidobacterium longum* [ $1 \times 10^9$  CFU/capsule], *Bifidobacterium bifidum* [ $1 \times 10^9$  CFU/capsule], *Bifidobacterium infantis* [ $1 \times 10^9$  CFU/capsule] and *Lactobacillus acidophilus* [ $2 \times 10^9$  CFU/capsule]. Thus, in our hospital the following medication was administered enterally via a nasogastric tube: an enteral antibiotic gentamicin sulphate [7.5 mg/kg BW–12 hourly], an antifungal agent nystatin [2.500 IU/kg BW–6 hourly] and a synbiotic [Lac- toG: BW less than 2000g– $\frac{1}{4}$  capsule pulveris 12 hourly; BW>2000g– $\frac{1}{2}$  capsule pulveris 12 hourly] [Harutyunyan A *et al.*, 2019c].

The study for determination of the effectiveness of the multi-modal 3 component NEC prophylaxis per oral scheme (Gentamicin + Nystatin + LactoG synbiotic) in complex treatment of NEC and its prevention was held at the NICU of Muratsan Clinical Complex at Yerevan State Medical University, Armenia. The 33 newborns underwent the digital plain-film abdominal radiographs on second day after hospital admission and administration of multi-modal 3 component enteral NEC prophylaxis scheme during period of 15<sup>th</sup> October 2018 to 5<sup>th</sup> December 2018. The digital x-ray examinations were repeated on 3<sup>rd</sup> and 5<sup>th</sup> days in dynamic. The results were: in all 9 newborns with NEC on 1<sup>st</sup> day the intestinal pneumatosis in different manifestations has been revealed by x-ray (24 hours after receive of the multi-modal 3 component enteral NEC prophylaxis scheme). On 3<sup>rd</sup> and 5<sup>th</sup> days the positive dynamic of intestinal pneumatosis was described by digital x-ray and this corresponded to a positive clinical dynamic [Harutyunyan A et al., 2019b].

In 24 newborns who admitted to NICU the clinical diagnose of NEC was not present. In 14 cases (out of 24 NoNEC) intestinal pneumatosis was absent during all period of x-ray examinations. In 9 cases (NoNEC) the “mild” early intestinal pneumatosis was present on first x-ray examination with positive dynamic on 3<sup>rd</sup> and 5<sup>th</sup> days of x-ray. In 1 case intestinal pneumatosis was absent on first x-ray examination. On 3<sup>rd</sup> day the intestinal pneumatosis was present in mild form (1+) by x-ray, and then on 5<sup>th</sup> day it hasn't revealed. In all 24 cases of NoNEC on 5<sup>th</sup> day no intestinal pneumatosis was present on x-ray [Harutyunyan A et al., 2019b].

The results (the conclusion was) of the study showed that multi-modal 3 component NEC prophylaxis per oral scheme (Gentamicin + Nystatin + LactoG synbiotic) has a positive effect on the resolution of process of intestinal damage manifested in the form of intestinal pneumatosis in newborns with necrotizing enterocolitis. Also the multi-modal 3 component NEC prophylaxis per oral scheme has a clear effect on the prevention of NEC developmental process [Harutyunyan A et al., 2019b].

The single-center, retrospective, case-control study was conducted at the NICU of Muratsan Clinical Complex of Yerevan State Medical University. The Graz protocol of multi-modal three-component regimen for NEC prevention was introduced, but the analysis did not include any patients of Graz. In this present analysis, only neonates with an already established diagnosis of NEC in all

stages were included. The impact of the multi-modal three-component enteral medication regimen was analyzed by comparing Intervention versus Control Group using the following primary outcome parameters: intestinal perforation, surgical interventions and mortality during the observational periods. A secondary outcome parameter included the stage of NEC according to Bell at establishment of diagnosis and the maximum stage reached. Diagnosis of NEC was carried out according to accepted international standards using the Bell stages. Additionally, to the enteral medication, all infants received a standard iv Antibiotics regimen, which consisted of penicillin G (100 mg/kg BW 12 hourly), and gentamicin (4 mg/kg BW 24 hourly). An indication for surgical laparotomy was the presence of intestinal perforation diagnosed using abdominal x-ray. Analyzed hospital records included information regarding demographics, prescribed medications, procedures and diagnoses of infants. Demographic data included sex, birth weight (BW), gestational age (GA) and Apgar score. Whether mortality was due to NEC or other causes was defined according to the results of autopsy and histological examination [Springer SC, Annibale DJ., 2017; Harutyunyan A et al., 2020]. Out of 200 infants with NEC, 51 (26%) died. Significantly fewer infants died in the Intervention Group (13 infants, 13%) compared to the Control Group (38 infants, 40%) ( $p = 0.0001$ , OR: 0.2, CI – 0.1-0.4). According to the autopsy reports, mortality was directly linked to NEC in 15 infants (16%) in the Control Group, but in none (0%) in the Intervention Group ( $p = 0.0001$ ). Furthermore, the number of deaths not associated with complications due to NEC (pneumothorax, intracranial hemorrhage and septicemia) was 13 (13%) in the Intervention Group, compared to 28 infants (30%) in the Control Group ( $p = 0.003$ , OR: 0.34, CI – 0.16-0.7). Hence, both overall mortality and NEC-related mortality were reduced significantly in the Intervention Group compared to the Control Group. No infant in the Intervention Group (0%) presented with an intestinal perforation, as compared to 15 infants (16%) in the Control Group ( $p = 0.0001$ ). All 15 infants with intestinal perforation from the Control Group were treated surgically, three received abdominal drainage and 12 underwent laparotomy. The conclusion was that the multi-modal three-component enteral medication regimen was introduced as a new therapeutic approach in neonates with NEC. Introduction of this regimen resulted in significantly reduced

NEC-associated morbidity and mortality in the Intervention Group. This was the first study to report the use of an enteral medication regimen to reduce NEC-associated morbidity and mortality. The results of the study potentially have great impact on treatment of NEC in the future, especially in countries with a high NEC incidence. Nevertheless, as the present data were only observational data, they were only hypothesis generating. Further prospective and randomized studies with larger cohorts are needed to verify the effects described in the present study [Harutyunyan A et al., 2020].

In medicine, a biomarker is a measurable indicator of the severity or presence of some disease state. More generally a biomarker is anything that can be used as an indicator of a particular disease state or some other physiological state of an organism.

A biomarker can be a substance that is introduced into an organism as a means to examine organ function or other aspects of health. More specifically, a biomarker indicates a change in expression or state of a protein that correlates with the risk or progression of a disease, or with the susceptibility of the disease to a given treatment. Biomarkers can be characteristic biological properties or molecules that can be detected and measured in parts of the body like the blood or tissue. They may indicate either normal or diseased processes in the body. Biomarkers can be specific cells, molecules, or genes, gene products, enzymes, or hormones. Complex organ functions or general characteristic changes in biological structures can also serve as biomarkers. Although the term biomarker is relatively new, biomarkers have been used in pre-clinical research and clinical diagnosis for a considerable time. For example, body temperature is a well-known biomarker for fever. Blood pressure is used to determine the risk of stroke. It is also widely known that cholesterol values are a biomarker and risk indicator for coronary and vascular disease, and that C-reactive protein is a marker for inflammation. The recent research suggests that  $\alpha$ - and  $\beta$ -synucleins are expressed in colorectal cancer as well, which allows them to be considered biomarkers for the disease severity assessment [Avagyan S, Zilfyan A, 2020].

Biomarkers are useful in a number of ways, including measuring the progress of disease, evaluating the most effective therapeutic regimes for a particular cancer type, and establishing long-term susceptibility to cancer or its recurrence. The parameter can be chemical, physical or biological. In molecular terms biomarker is the subset of markers that

might be discovered using genomics, proteomics technologies or imaging technologies. Biomarkers play major roles in medicinal biology. Biomarkers help in early diagnosis, disease prevention, drug target identification, drug response etc.

#### DISCUSSION

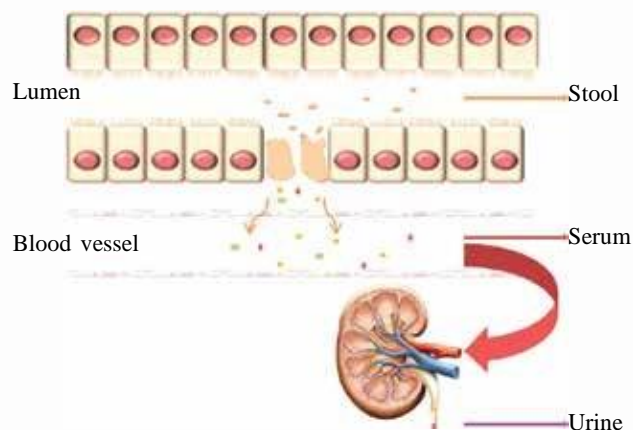
Necrotizing enterocolitis (NEC) is severe disease of gastrointestinal tract, yet its early symptoms are nonspecific, easily interchangeable with sepsis. Therefore, reliable biomarkers for early diagnostics are needed in clinical practice [Coufal S et al., 2016].

One of the promising trends in early diagnosis of NEC is use of biomarkers. The biomarkers used in prognosis and diagnosis of NEC are relative nonspecific as other noninvasive and less invasive methods [Nantais-Smith L et al., 2015].

Necrotizing enterocolitis often has a rapid onset with few, if any, antecedent signs that can be used to reliably predict its occurrence. Its rapid onset and progression to death, as well as its severe morbidity when the infant survives, begs for early diagnostic tools that may be used in determining those infants who would be at greatest risk for development of the disease and for whom early preventative measures could be targeted. Although studies have suggested efficacy of several techniques such as breath hydrogen, inflammatory mediators in blood, urine or stool, and genetic markers, these all have drawbacks limiting their use [Christopher Y et al., 2009].

The clinical application of biomarkers may include surveillance, early diagnosis, predicting severity and prognosis of disease, or response to therapy. The consensus among experts is that biomarkers may find the greatest immediate utility in providing for an early diagnosis of NEC or for identifying those premature infants most at risk of NEC prior to overt clinical manifestations. The rationale for this framework is that early or preclinical disease recognition will provide the greatest possible opportunity for disease prevention or mitigation. Since the intestine and colon cannot be directly sampled, research has focused on the development of noninvasive measures for NEC biomarkers. From a practical perspective, there are multiple approaches to noninvasive interrogation including the sampling of neonatal stool, urine, and serum (Figure). [Kewei W et al., 2019].

The most expansive experience has been acquired among studies that have utilized fecal, urine, or serum biomarkers that can contribute to



**FIGURE.** Source of the noninvasive biomarker for NEC. When intestinal epithelial cells are damaged, some cell component can be detached, mixed with the feces, and then excreted. Some proteins or cytokines are released into the bloodstream and then excreted by the kidneys [Wang K et al., 2019]

the diagnosis of NEC [Kewei W et al., 2019].

Several biomarkers described in literature as detected in the blood need to be specifically assessed for their prognostic value. Number of blood markers are promising diagnostic and prognostic measures, including:

- Acute-phase biomarker (C-reactive protein, TNF  $\alpha$ , IL-6 and IL-8, etc.) [Niemarkt H et al., 2015].
- Organ-specific biomarkers (intestinal fatty acid-binding protein, liver fatty acid-binding protein, faecal calprotectin, trefoil factor 3 and claudin-3 etc.) [Ng P et al., 2014].
- Urine fibrinogen peptide used in combination with 27 clinical parameters (FGA1826, FGA1883 and FGA2659) [Sylvester K et al., 2014].

Amongst this variety of biomarkers molecules, based on literature, one of the most promising for NEC seems to be intestinal fatty acid-binding protein, which is a cytoplasmic protein (part of enterocyte lipid metabolism) [Heida F et al., 2015; Schurink M et al., 2015]. In case of damage of enterocyte, the fatty acid binding protein is getting released into circulation and can be detected in blood serum and urine. As enterocytes damage draws a parallel with intestinal necrosis, this biomarker has been recommended as useful noninvasive measure in the prediction of NEC [Schurink M et al., 2015]. Intestinal Fatty Acid-Binding Protein

(I-FABP) is one of the most widely studied potential biomarkers of NEC. I-FABP is released into the bloodstream upon intestinal injury and is excreted by the kidneys. Thus, I-FABP can be detected in either blood or urine as a potential biomarker of intestinal mucosal damage caused by NEC. Gollin G. and co-authors reported that elevated I-FABPu (in urine) was sensitive and specific predictive biomarker for NEC one day before clinical manifestations [Gollin G et al., 2014]. Levels of urinary I-FABP are higher in NEC patients than in sepsis patients or healthy infants with a sensitivity of 81% and a specificity of 100%. It has also been observed that the length of intestinal resection in surgical NEC was closely related to serum or urinary I-FABP levels at the occurrence of the disease. Moreover, I-FABPu correlated significantly with serum IL-6 and lactate during the first eight hours of the disease. Together, these results suggest that I-FABP may be a clinically valid biomarker for NEC in the future [Kewei W et al., 2019].

During the implementation of multi-modal per oral scheme to newborns both for NEC prevention and treatment in NICU of “Muratsan” Clinical Complex, the main problems were:

- NEC diagnostic at early stages.
- NEC stage definition.
- The effectiveness of multi-modal per oral scheme in NEC prevention.
- The effectiveness of multi-modal per oral scheme in NEC treatment.
- The prediction of treatment schemes in NEC.

#### CONCLUSION

In modern days, biomarkers widely used for diagnose and prediction in oncology, cardiology, even in neurology. Necrotizing enterocolitis is one of the most severe acquired diseases affecting pre-term neonates. Early diagnosis remains elusive which continues to prompt human subject studies in the search for NEC-associated biomarkers that may provide for early diagnosis or the recognition of high-risk subcohorts with sufficient precision to facilitate preventive measures. We are planning for prospective study with clinical use of intestinal fatty acid-binding protein in diagnose and prediction of necrotizing enterocolitis in newborns.

#### Abbreviations:

NEC – Necrotizing enterocolitis in newborns, ICU – intensive care unit, I-FABP – Intestinal Fatty Acid-Binding Protein, NICU – neonates’ intensive care unit

## REFERENCES

1. Avagyan SA, Zilfyan AV. 180 Polyamines and synucleins in the diagnosis, pathogenesis and prognosis of neurological and oncological diseases. Edition approved and recommended by Yerevan State Medical University named M. Heratsi, Armenia, Yerevan. 2020; 185p. ISBN 978-9939-65-220-7
2. Battersby C, Longford N, Mandalia S, Costeloe K, Modi N, UK Neonatal Collaborative Necrotising Enterocolitis (UKNC-NEC) study group. Incidence and enteral feed antecedents of severe neonatal necrotising enterocolitis across neo-natal networks in England, 2012–13: a whole-population surveillance study. *The Lancet Gastroenterology & Hepatology*. 2017; 2(1): 43-51
3. Battersby C, Santhalingam T, Costeloe K, Modi N. Incidence of neonatal necrotising enterocolitis in high-income countries: a systematic review. *Arch Dis Child Fetal Neonatal Ed*. 2018; 103(2): F182-F189. 10.1136/archdischild-2017-313880
4. Bell MJ, Ternberg JL, Feigin RD, Keating JP, Marshall R., *et al.* Neonatal necrotizing enterocolitis. Therapeutic decisions based upon clinical staging. *Ann Surg*. 1978; 187: 1-7
5. Berkhout DJ, Klaassen P, Niemarkt HJ, de Boode WP, Cossey V., *et al.* Risk factors for necrotizing enterocolitis: a prospective multicenter case-control study. *Neonatology*. 2018; 114(3): 277-284
6. Berrington JE. CD64 Measurement in Neonatal Infection and Necrotising Enterocolitis. Newcastle, Newcastle-upon-Tyne, United Kingdom, NE77DN. 2017
7. Claud EC. Anti-inflammatory and anti-allergy agents. *Med Chem*. 2009; 8(3): 248-259
8. Coufal S, Kokesova A, Tlaskalova-Hogenova H, Snajdauf J, Rygl M, Kverka M. Urinary intestinal fatty acid-binding protein can distinguish necrotizing enterocolitis from sepsis in early stage of the disease. *J Immunol Res*. 2016; 2016: 5727312
9. Eaton S, Rees CM, Hall NJ. Current research on the epidemiology, pathogenesis, and management of necrotizing enterocolitis. *Neonatology*. 2017; 111(4): 423-430
10. Elgin TG, Kern SL, McElroy SJ. Development of the neonatal intestinal microbiome and its association with necrotizing enterocolitis. *Clinical Therapeutics*. 2016; 38(4): 706-715
11. Fitzgibbons SC, Ching Y, Yu D, Carpenter J, Kenny M., *et al.* Mortality of necrotizing enterocolitis expressed by birth weight categories. *Journal of Pediatric Surgery*. 2009; 44(6): 1072-1076
12. Gollin G, Stadie D, Mayhew J, Slater L, Asmerom Y., *et al.* Early detection of impending necrotizing enterocolitis with urinary intestinal fatty acid-binding protein. *Neonatology*. 2014; 106(3): 195-200
13. Good M, Sodhi CP, Hackam DJ. Evidence-based feeding strategies before and after the development of necrotizing enterocolitis. *Expert Review of Clinical Immunology*. 2014; 10(7): 875-884
14. Harutyunyan AS, Badalyan AR, Lorenc DV, Babloyan AS, Hovhannisyan MG, Eyrarnjyan GG. The inconsistency of clinical and histological diagnosis in neonates with necrotizing enterocolitis. *The New Armenian Medical Journal*. 2019a; 13(1): 104-111
15. Harutyunyan AS, Badalyan AR, Gzoyan NA, Babloyan AS. The dynamic X-ray of intestinal pneumatosis in neonates who received multi-modal enteral medication regimen both in treatment and prevention of necrotizing enterocolitis. *The New Armenian Medical Journal*. 2019b; 13(1): 115-122
16. Harutyunyan AS, Muradyan AA, Hovhannisyan MG, Badalyan AR, Lorenc DV., *et al.* The transformation of multi-modal 3 components preventive scheme into treatment protocol for necrotizing enterocolitis in newborns. *The New Armenian Medical Journal*. 2019c; 13(3): 89-102
17. Harutyunyan AS, Hovhannisyan MG, Badalyan AR, Muradyan AA, Babloyan AS. The introduction and results of multi-modal 3 component prophylaxis scheme both in prevention and treatment of necrotizing enterocolitis in newborns. *The New Armenian Medical Journal*. 2018; 12(4): 4-17
18. Harutyunyan AS, Urlesberger B, Muradyan AA, Hovhannisyan MG, Badalyan AR., *et al.* Introducing multi-modal enteral medication reduced morbidity and mortality associated with necrotising enterocolitis. *Journal: Acta Paediatrica*. Article ID: APA15466 Article DOI: 10.1111/apa.15466. Internal Article ID: 16829617. Accepted for print 02.07.2020; First published: 08 July 2020, <https://doi.org/10.1111/apa.15466>

19. Harutyunyan AS. The statistical review of cases of Necrotizing enterocolitis in newborns (NEC) at “Muratsan” Clinical Complex ICU of YSMU for period 2011 (VII) - 2016 (III). – ISSN 1829-3093, Academy of Sciences RA, Institute of Surgery “MICKAE-LYAN”, Ministry of Health, RA “Armenian Surgery Herald” named by H.S. Tamazyan, 2017; Periodic scientific collection. Published annually. pp. 112-128
20. Heida FH, Hulscher JB, Schurink M, Timmer A, Kooie EM., et al. Intestinal fatty acid-binding protein levels in necrotizing enterocolitis correlate with extent of necrotic bowel: results from a multicenter study. *J Pediatr Surg.* 2015; 50: 1115-1118
21. Huda S., Chaudhery S., Ibrahim H, Pramanik A., Neonatal necrotizing enterocolitis: Clinical challenges, pathophysiology and management, *Pathophysiology* 2014, 21(1) 3-12, doi: 10.1016/j.pathophys.2013.11.009
22. Janssen LM, Miyake H, Hock A, Daneman A, Pierro A, Offringa M. Value of abdominal ultrasound in management of necrotizing enterocolitis: a systematic review and meta-analysis. *Pediatr Surg Int.* 2018; 34(6): 589-612. 10.1007/s00383-018-4259-8
23. McElroy SJ. Unraveling the enigma that is neonatal necrotizing enterocolitis. *Journal of Perinatology*, 2014; 34(10): 729-730.
24. Nantais-Smith L, Kadrofske M. Noninvasive biomarkers of necrotizing enterocolitis. *J Perinat, Neonatal Nurs.* 2015; 29: 69-80
25. Neu J, Pammi M. Pathogenesis of NEC: impact of an altered intestinal microbiome. *Seminars in Perinatology.* 2017; 41(1): 29-35
26. Neu J. Necrotizing enterocolitis. The Search for a Unifying Pathogenic Theory Leading to Prevention. Published online 2005 Jun 19. doi: 10.1016/S0031-3955(05)70413-2. PMID: 1614608
27. Ng PC. Biomarkers of necrotising enterocolitis. *Semin Fetal Neonatal Med.* 2014; 19: 33-38
28. Niemarkt HJ, de Meij TG, van de Velde ME, van der Schee MP, van Goudoever JB., et al. Necrotizing enterocolitis: a clinical review on diagnostic biomarkers and the role of the intestinal microbiota. *Inflamm Bowel Dis.* 2015; 21: 436-444
29. Qian T, Zhang R, Zhu L, Shi P, Yang J., et al. Necrotizing enterocolitis in low birth weight infants in China: mortality risk factors expressed by birth weight categories. *Pediatrics and Neonatology.* 2017; 58(6): 509-515
30. Robinson JR, Rellinger EJ, Hatch LD, Weitkamp JH, Speck KE., et al. Surgical necrotizing enterocolitis. *Seminars in Perinatology.* 2017; 41(1): 70-79
31. Sankaran K, Puckett B, Lee DS, Seshia M, Boulton J., et al. Variations in incidence of necrotizing enterocolitis in Canadian neonatal intensive care units. *Journal of Pediatric Gastroenterology and Nutrition.* 2004; 39(4): 366-372
32. Schmolzer G, Urlesberger B, Haim MJ, Kutschera G, Pichler E., et al. Multi-modal approach to prophylaxis of necrotizing enterocolitis: clinical report and review of literature. *Ped Surgery Int.* 2006; 22: 573-580
33. Schurink M, Kooi EM, Hulzebos CV, Kox RG, Groen H., et al. Intestinal fatty acid-binding protein as a diagnostic marker for complicated and uncomplicated necrotizing enterocolitis: a prospective cohort study. *PLoS One.* 2015; 10(3): e0121336
34. Springer SC, Annibale DJ. Which histologic findings are characteristic of necrotizing enterocolitis? *Necrotizing enterocolitis; Pediatrics: Cardiac Disease and Critical Care Medicine; Medscape.* 2017
35. Stoll BJ, Hansen NI, Bell EF, Walsh MC, Carlo WA., et al. Trends in care practices, morbidity, and mortality of extremely preterm neonates, 1993-2012. *Journal of the American Medical Association.* 2015; 314(10): 1039-1051
36. Sylvester KG, Ling XB, Liu GY, Kastenberg ZJ, Jun Ji., et al. A novel urine peptide biomarker-based algorithm for the prognosis of necrotising enterocolitis in human infants. *Gut.* 2014; 63: 1284-1292
37. Wang K, Tao G, Sun Zh, Sylvester KG. Recent potential noninvasive biomarkers in necrotizing enterocolitis. *gastroenterology research and practice.* Volume 2019, Article ID 8413698, 9 pages. <https://doi.org/10.1155/2019/8413698>
38. Warner BB, Deych E, Zhou Y, Hall-Moore C, Weinstein GM., et al. Gut bacteria dysbiosis and necrotising enterocolitis in very low birthweight infants: a prospective case-control study. *Lancet.* 2016; 387(10031): 1928-1936
39. Young C, Sharma R, Handfield M, Mai V, Neu J. Biomarkers for Infants at Risk for Necrotizing Enterocolitis: Clues to Prevention? *Pediatric research, Printed in USA.* 0031-3998/09/6505-0091R. 2009; 65(5 Pt 2)
40. Yu Y, Klemann C, Feng X, Ginzl M, Vieten G., et al. Increased inflammatory reaction to intestinal ischemia-reperfusion in neonatal versus adult mice. *European Journal of Pediatric Surgery.* 2015; 25(1): 46-50